Artelon® FLEXIBLE HEALING

CLINICAL CASE STUDY

DELTOID LIGAMENT TEAR: RECONSTRUCTION USING AN ARTELON® FLEXBAND™ FOR DYNAMIC AUGMENTATION

Steven K. Neufeld, MD, Orthopedic Surgeon, Centers for Advanced Orthopaedics (CAO), Falls Church, VA

TECHNOLOGY OVERVIEW

Artelon is a Dynamic Matrix™ for tendon and ligament reconstruction. It mimics the body's natural healing matrices to create repairs that are both strong and highly elastic.[1] These features have been proven[2,3,4] to:

- **Restore** kinematics
- **Resist** failure from necrosis
- **Regenerate** native tissue through load sharing

Artelon is extremely inert, and less reactive than common biomaterials such as titanium, polystyrene and suture.[5] It integrates into the repair site and scaffolds new tissue growth. Its high compliance permits load sharing, which stimulates rapid tissue remodeling through mechanotransduction.[6] Artelon maintains its properties for five years, then dissolves in water and is eliminated from the body.

The current case involves a patient with a deltoid ligament tear causing ankle pain and medial ankle instability.

CLINICAL HISTORY

A 52-year-old healthy male presented after sustaining a slip and fall off of a ladder. Clinically he presented with pain and swelling along both the medial and lateral sides of his ankle. Radiographs revealed an obvious fibular fracture with a subsequent deltoid tear, allowing the mortise to widen (Figures 1 & 2)

INTRAOPERATIVE FINDINGS:

Upon incision, the ankle was grossly unstable with both the fractured fibula and the ruptured deltoid ligament confirmed. (Figure 3,4) While the fracture could be managed with open reduction and internal fixation, the large ligamentous defect and degenerated deltoid tissue made primary ligament repair impossible. Reconstruction & augmentation was necessary and a 0.7 x 8cm Artelon FlexBand was determined to be strong enough to help sustain the forces across the ruptured ligament. (Figure 3 & 4)

Figures 1&2: Radiographs of the right foot/ankle showing fractured fibula and wide mortise.

Figures 3&4: Intraoperative images showing torn deltoid ligament.

References
1. *Gisselfalt et al, Biomacromolecules 2002, 3, 951-958.*
2. *Liljensten et al, J. Biomater. Sci: Materials in Medicine 13 (2002) 351-359*
3. *Peterson et al, Knee Surg Sports Traumatol Arthrosc (2014) 22:2109–2120.*
4. *Peterson et al., The Anterior Cruciate Ligament: Reconstruction and Basic Science. 2nd ed., Elsevier 2018.*
5. *Gretzer et al, J. Biomater. Sci. Polymer Edn, Vol. 17, No. 6, pp. 669–687 (2006)*
6. *Gersoff et al, J Knee Surg. 2018 Apr 27.*

DELTOID LIGAMENT TEAR: RECONSTRUCTION USING AN ARTELON® FLEXBAND™ FOR DYNAMIC AUGMENTATION

Steven K. Neufeld, MD, Orthopedic Surgeon, Centers for Advanced Orthopaedics (CAO), Falls Church, VA

SURGICAL INTERVENTION

After the fibula was reduced and stabilized with a plate and screws, an incision was made along the medial ankle in order to inspect the medial joint and revealed a torn deltoid ligament. Therefore, the medial malleolus deltoid insertion site was debrided and an anchor was used to secure a 0.7 x 8cm FlexBand matrix to the distal tibial (Figures 5-7). Next, the unattached end of the FlexBand was pulled into 10-20% tension and secured directly to the talus deltoid insertion point with a second anchor (Figures 8-9). Excess FlexBand was trimmed away and the remaining native deltoid ligament was wrapped around the implanted matrix (Figure 10). Final manipulation felt stable and x-rays confirmed that the ankle had been reduced (Figure 11).

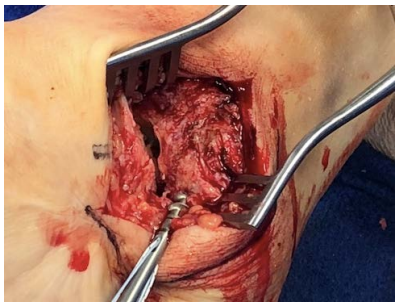

Figure 5: Inserting anchor into the deltoid origin/ medial malleolus.

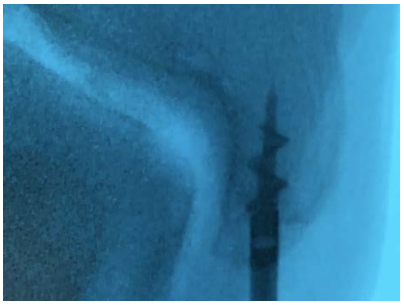

Figure 6: Anchor placement confirmed with fluoroscopy.

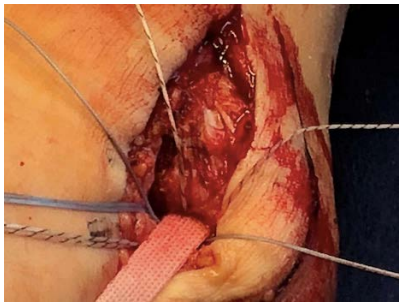

Figure 7: Securing FlexBand matrix to the medial malleolus/deltoid origin.

Figure 8: Anchor in the deltoid insertion (talus). Tensioned and secured the FlexBand.

Figure 9: Anchor placement confirmed with fluoroscopy.

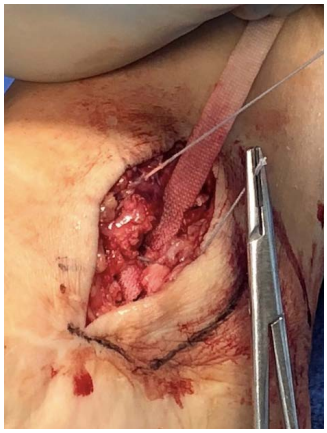

Figure 10: Deltoid remnants wrapped around the FlexBand matrix as part of repair.

Figure 11: Post-op radiographs showing reduced mortise.

FOLLOW UP

Immediately post-op, the patient had a short leg splint placed. At his 1-week follow-up, he was placed in a short leg cast, remained non-weight bearing and physical therapy started at 6 weeks. He continued to rehab well and at 12 weeks returned to light exercise. Deltoid ligament reconstruction maintained the stability of the ankle.

CONCLUSION

This 52 year-old active man sustained an unstable ankle fracture with torn deltoid and underwent a successful reconstruction utilizing Artelon FlexBand augmentation. Through the procedure, we achieved a strong and reliable repair, which allowed him an early return to full activities. His ankle remained stable. Deltoid reconstruction including Artelon's Dynamic Matrix technology is safe and effective, with the capability of supporting an early return to activities.

2252 Northwest Pkwy SE, Suite G, Marietta, GA 30067 800.610.3446 customerservice@artelon.com

4000048 Rev. A